

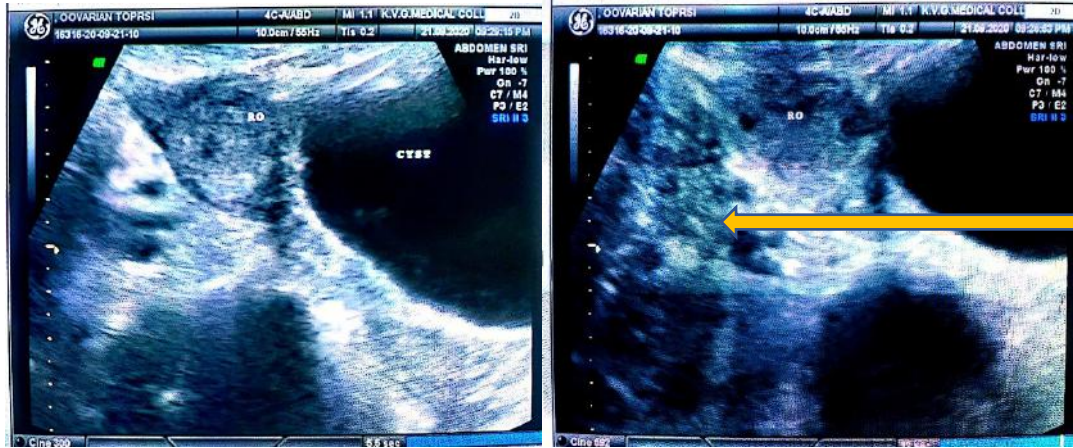
A CASE OF RIGHT OVARIAN TORSION

- 31 YR OLD FEMALE CAME WITH C/O SEVERE RIGHT SIDED LOWER ABDOMINAL PAIN AND MULTIPLE EPISODES OF VOMITING FOR ONE DAY.
- HER MENSTRUAL HISTORY WAS NORMAL.
- SHE WAS MARRIED SINCE 5 YRS AND HAS TWO LIVING CHILDREN.
- NO SIGNIFICANT PAST MEDICAL/SURGICAL/FAMILY HISTORY.

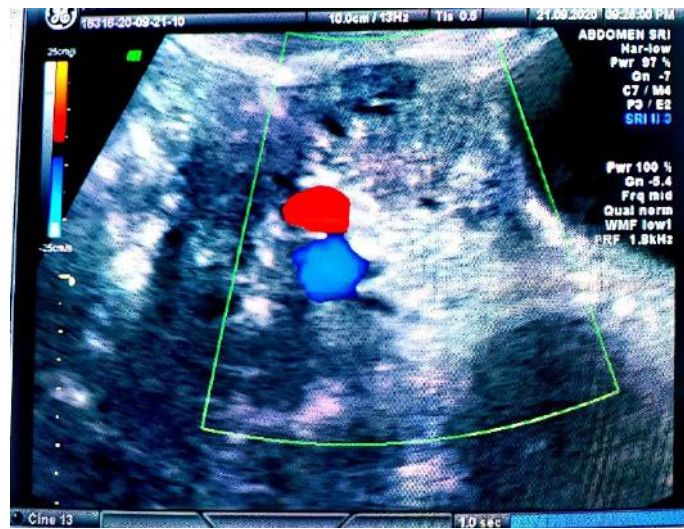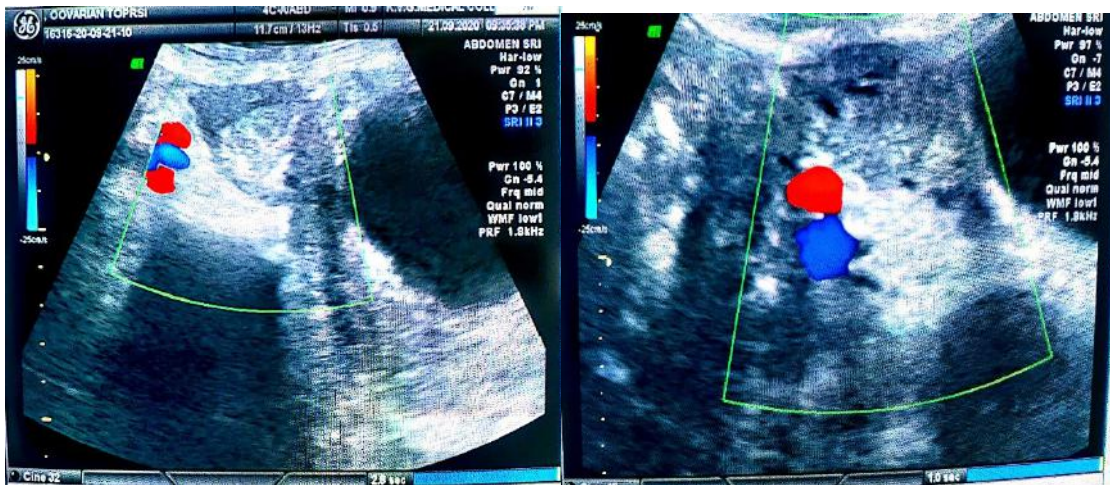ABDOMEN EXAMINATION AND INVESTIGATION

- PALPATION-TENDERNESS PRESENT IN THE RIGHT INFERIOR QUADRANT AND RIGHT ILIAC FOSSA
- ALL ROUTINE INVESTIGATIONS-BLOOD, URINE, RFT WERE DONE AND WERE FOUND NORMAL
- PATIENT WAS REFERRED FOR EMERGENCY USG ABDOMEN AND PELVIS

ABDOMINAL AND PELVIC ULTRASONOGRAPHY WAS PERFORMED



Torsion knot



LARGE THICK WALLED CYST MEASURING 10.6 X 6.5 CM SEEN IN THE MIDLINE POSSIBLY ARISING FROM RIGHT ADNEXA WITH TORSION KNOT IN RIF MEASURING 6X3 CM COMPRESSING URINARY BLADDER. RIGHT OVARY NOT VISUALISED SEPARATELY

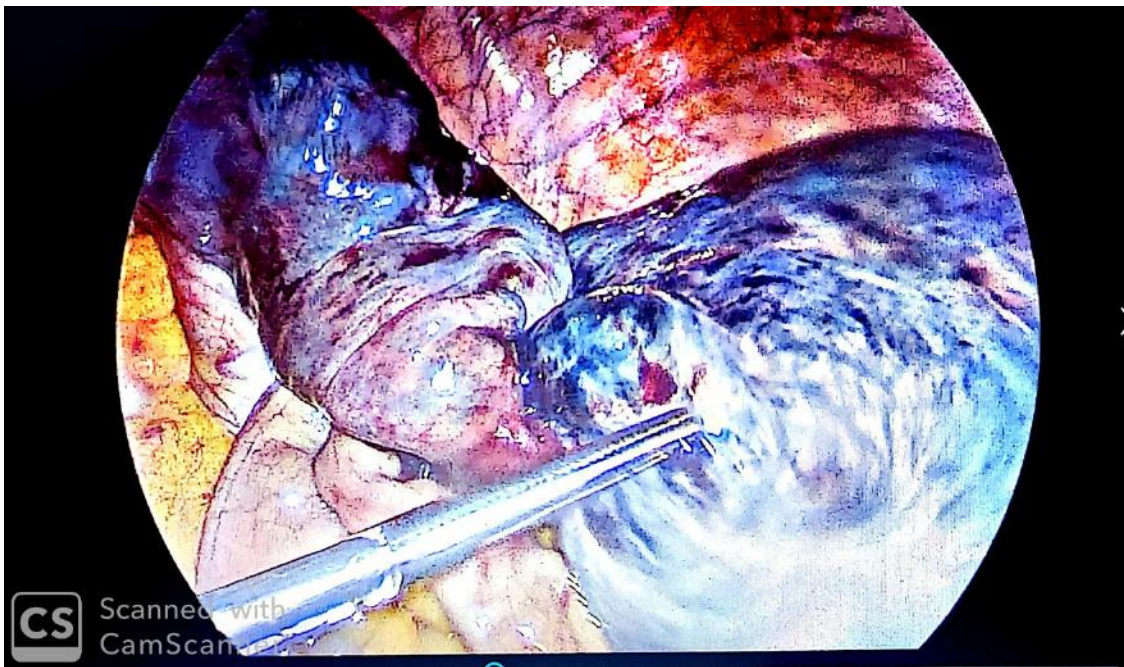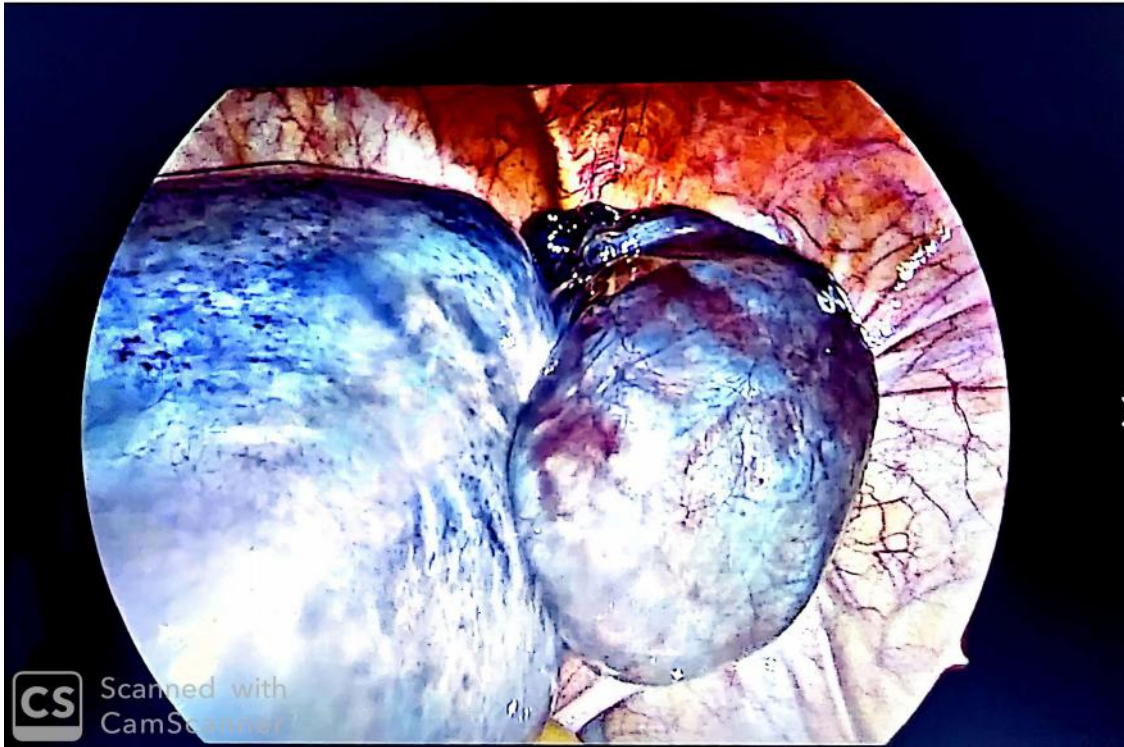
IMPRESSION: LARGE THICK WALLED CYSTIC LESION IN THE MIDLINE WITH KNOT SEEN IN RIF - POSSIBILITY OF RIGHT OVARIAN TORSION

MANAGEMENT:

PATIENT UNDERWENT LAPROSCOPIC RIGHT OVARIOTOMY WITH SALPINGECTOMY FOLLOWED BY COLPOTOMY.

INTRAOPERATIVE FINDINGS

- RIGHT OVARIAN CYST OF ABOUT 10X7 CM WITH TORSION NOTED
- 6 KNOTS UNTWISTED
- CYST WALL PUNCTURED, STRAW COLOUR FLUID ASPIRATED
- CYSTECTOMY ATTEMPTED
- SINCE THE CYST WAS FRIABLE, OVARIOTOMY WITH SALPINGECTOMY
- SPECIMEN REMOVED BY COLPOTOMY.



POST OPERATIVE COMPLICATIONS: NONE.